

Utilization of an ovine collagen dressing with an intact extracellular matrix (CECM) within a dual-protocol algorithm to improve wound closure times and reduce expenditures in a VA Hospital.

• Daniel T. Ferreras, DPM, FAPWCA, Program Director • Sean Craig, RN, WOCN • Rebecca Malcomb, RN
Alexandria VA Wound Healing Center, Alexandria, LA

Introduction:

Wound healing involves a complex series of biochemical and cellular processes.¹ These sophisticated events can best be orchestrated when careful use of and adherence to an evidence based wound healing algorithm is utilized.² With the evolution and introduction of more costly cellular based biological grafts, which oftentimes have a limited shelf life window, the utilization of a CECM used from the first day of treatment can be a viable option in a wound care treatment plan. The CECM offers clinicians another option in a dual-protocol algorithm to help promote wound closure. When a broad-spectrum MMP reducing CECM³ was strategically utilized as part of a broader dual-protocol algorithm, it offered positive outcomes to wound closure. It also offers further momentum toward the development of a clinical model that couples organized fundamental wound closure tenets and the use of reasonably priced collagen platforms.

Methodology:

The Alexandria VA Wound Healing Center features state of the art, 21st century technologies that can provide military veterans suffering from diabetic, venous leg and lower extremity pressure ulcers access to some of the most up-to-date wound healing diagnostic and treatment strategies available. The center established consulting protocols and developed a clinically functional, dual-protocol algorithm that can effectively deliver a standardized method of assessing, treating and managing wounds. (See Figure 1).

CECM was introduced in the Wound Healing Center to determine the feasibility of using a unique collagen dressing that combines strength, simplicity and savings. CECM was a first-line treatment strategy in a dual-protocol algorithm that combined both a decision and a treatment protocol. The number of wound resolutions, amount of advanced graft usage and CECM usage was plotted against a function of time. (See Figure 2). Our clinical decision to continue with conservative treatment or bridge to a more advanced product was based on whether there was a 30%-50% wound size reduction over 4 weeks.⁴ If wound size continued to contract after 4 weeks of conservative treatment, CECM remained the primary dressing. If wound contraction stalled or increased after 4 weeks, an advanced biologic was chosen in lieu of CECM to reach our resolution endpoint. Complete and sustained wound resolution was defined as closure by secondary intention⁵ with repopulation of healthy granular tissue to wound base⁶ and 100% epithelialization with no drainage.⁷

Conclusion:

This abstract demonstrates two endpoints. First, the use of a comprehensive dual protocol algorithm, utilizing a native MMP-reducing collagen dermal template (CECM) as first line wound management, was a success. Secondly, after the introduction of the CECM in this VA hospital, the number of wound resolutions were increased by 70% and advanced grafts expenditures were reduced by 71.6%.

Figure 1

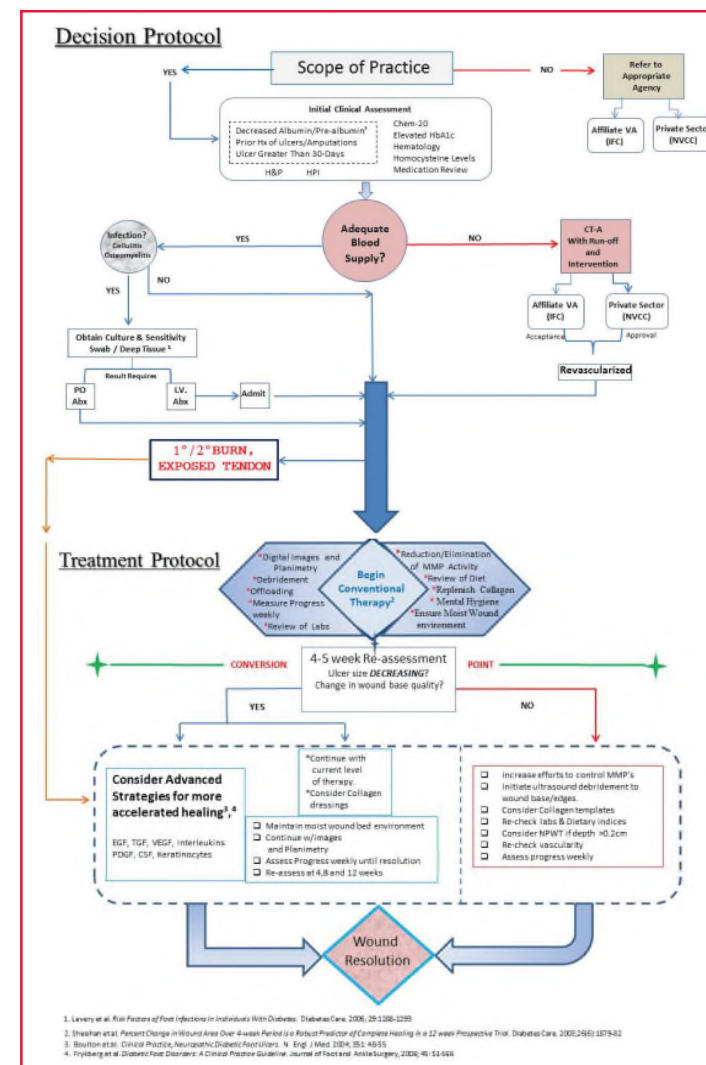
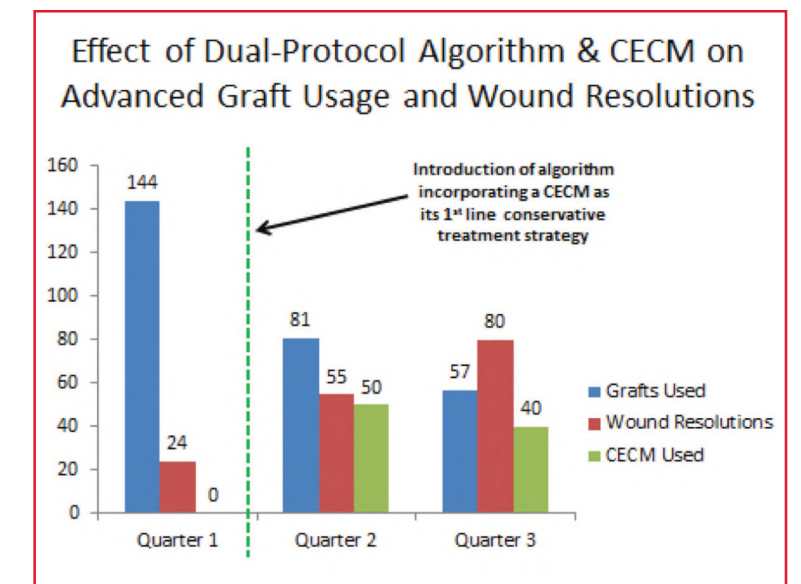


Figure 2



REFERENCES

1. Enoch, S., & Price, P. (2004). Cellular, molecular and biochemical differences in the pathophysiology of healing between acute wounds, chronic wounds and wounds in the aged. *World Wide Wounds*.
2. Sibbald, R. G., Ovington, L. G., Ayello, E. A., Goodman, L., & Elliott, J. A. (2014). Wound bed preparation 2014 update: management of critical colonization with a gentian violet and methylene blue absorbent antibacterial dressing and elevated levels of matrix metalloproteinases with an ovine collagen extracellular matrix dressing. *Advances in skin & wound care*, 27(3, SUPPL. 1), 1-6.
3. Endoterm brochure, Hollister, Inc.
4. Sheehan P, Jones P, Caselli A, Giurini JM, Veves A. Percent change in wound area of diabetic foot ulcers over a 4-week period is a robust predictor of complete healing in a 12-week prospective trial. *Diabetes Care* 2003; 26: 1879-82.
5. Swezey, L. (2011) *Wound Care Principles: Three Types of Wound Closure*. Wound Source, November 7.
6. Dunn, D., Jay Phillips Professor and Chairman of Surgery, University of Minnesota. *Wound Closure Manual*. Ethicon, Inc. Chapter one: Wound Healing and Management, Page 7.
7. LA Lavery, J Fulmer, KA Shebetka, et al. The efficacy and safety of Graftix(R) for the treatment of chronic diabetic foot ulcers: results of a multi-centre, controlled, randomised, blinded, clinical trial. *Int Wound J* 2014; 11:554-560.